

Benign Hereditary Nephritis

Alan S. Peterson, MD
John J. Schubert, MD
Lancaster, Pennsylvania

The diagnosis, prognosis, and heredity of glomerulonephritis, in 207 members of one family over five generations was determined. No evidence of significant renal insufficiency or renal associated mortality was found. A history of urinary tract infections was obtained from 58 percent of those with hematuria. Several of those with nephritis also had high-frequency hearing losses. Two females with histories of urinary infections had elevated levels of serum creatinine.

Many cases will probably be discovered if families are tested when a patient presents with benign recurrent hematuria with or without red blood cell casts. There may not be an obvious history of kidney disease or hematuria. Hereditary nephritis is not always a progressive renal disease.

In 1926, Bachr described 14 young adults with "a benign and curable form of hemorrhagic nephritis."¹ Hematuria in those young patients was discovered accidentally and seemed to persist without evidence of progressive renal disease. Subsequently, cases of both intermittent and persistent, benign microscopic hematuria have been discovered in all age groups.²⁻⁹ Study of renal function and morphology generally shows no evidence of renal disease. In a few cases a family history of hematuria or nephritis was elicited.⁶⁻⁹ The question arises whether some of these individual cases of nephritis were in fact familial. Hereditary nephritis has generally been considered to be progressive in at least

some individuals of all families affected.¹⁰

This paper describes five generations of a family with microscopic hematuria and a high incidence of red blood cell casts suggesting glomerulonephritis. No evidence of progression of renal disease was found. The large size of this family permits an assessment of the prognosis, mode of inheritance, and differential diagnosis of familial hematuria.

Methods and Study Population

Five generations and 207 members form the kindred that was studied in Lancaster and Chester Counties, Pennsylvania; Cecil County, Maryland; and

Ashe County, North Carolina. There are at least 584 members in the entire family.

The same physician evaluated one to three specimens of fresh, clean-voided, midstream urine. Care was taken not to include menstruating females. The following criteria were used to determine if an individual was affected: (1) The presence of four or more red blood cells per high power field and/or red blood cell casts; (2) if a family had both an affected parent and an affected child, the individual was presumed to be a carrier; and (3) neural hearing loss was considered significant if a decrease of 15 decibels or greater was present at 4,000 or greater cycles per second by standard audiometry. Albuminuria was measured by 0.2 percent tetrabromophenol blue indicator.* Serum creatinine was measured by the picric acid method utilizing the Jaffe reaction on the automated Technicon Autoanalyzer (normal 0.5 to 1.3 mg percent).

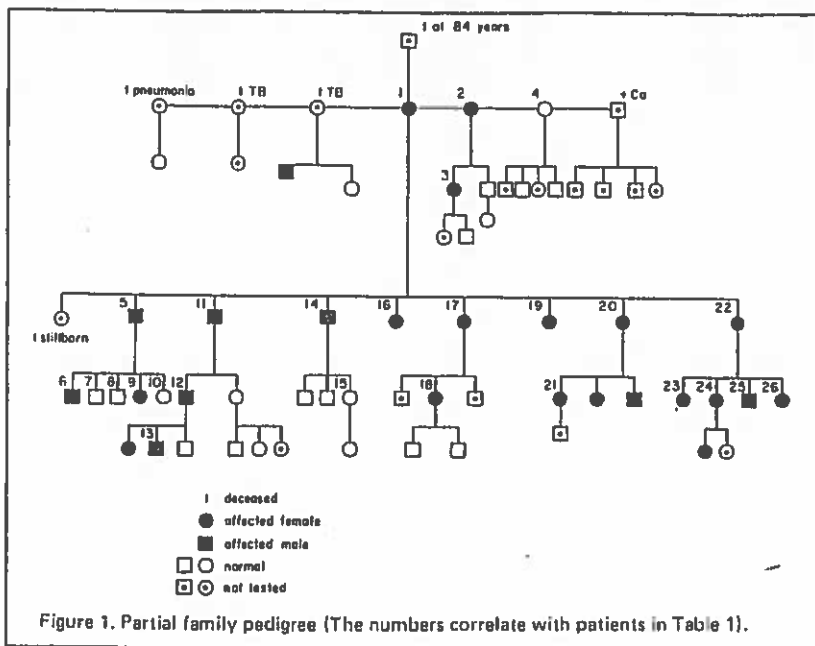
Case Reports

Case 1 (#9**). A 17-year-old fe-

From the Department of Family and Community Medicine, Lancaster General Hospital, Lancaster, Pennsylvania. Requests for reprints should be addressed to Dr. Alan S. Peterson, St. Joseph's Hospital, 250 College Avenue, Lancaster, Pa 17603.

*Bili Labstix, Ames Company, Inc., Elkhart, Indiana.

** Indicates pedigree number in Figure 1.



male (D.W.) was seen at the Quarryville Family Health Center in Quarryville, Pennsylvania, for a febrile illness in November 1973. She denied hematuria, but admitted to a history of urinary tract infections as well as allergies to radiologic iodinated contrast media and penicillin. Physical examination was normal. Urinalysis showed red cells, red blood cell casts, and trace proteinuria. Serum creatinine was 0.8 mg percent. A urinalysis two weeks later showed 50 to 100 red blood cells per high power field. Family history revealed the father (#6) and grandmother (#2) with histories of hematuria. This patient continues to have intermittent microscopic hematuria with red blood cell casts.

Case 2 (#1). A 77-year-old female (B.W.) was admitted to Lancaster General Hospital in Lancaster, Pennsylvania, in September 1973, with ab-

dominal pain. Past history revealed urinary tract infections, but no episodes of hematuria. Evaluation revealed a poorly functioning gallbladder, but the patient's abdominal pain resolved uneventfully. Urinalysis revealed microscopic hematuria. Intravenous pyelogram was normal and cystoscopy showed chronic trigonitis. Creatinine was 1.9 mg percent. A urine culture grew 15,000 colonies of streptococci and after penicillin, the hematuria persisted. Audiometry revealed a high-frequency hearing loss. The patient noted that several of her male and female ancestors had "kidney" disease which was not well defined and that all lived into their seventh and eighth decades. Subsequently, B.W. has had stable renal function, but persistent intermittent microscopic hematuria including red blood cell casts.

Case 3 (#14). A 50-year-old male (W.W.) was admitted to Lancaster General Hospital in December 1973, complaining of substernal chest pain with a past history of a coronary bypass and aortic valve replacement. Although he denied urinary tract infections or hematuria, microscopic hematuria was found. This was attributed to anticoagulation which, however, was in the therapeutic range. Serum creatinine was 1.0 mg percent. A high-frequency hearing loss was detected. The patient had experienced high noise levels in wartime. Renal function remains stable and microscopic hematuria recurs intermittently despite anticoagulation within a therapeutic range.

Case 4 (#2). A 51-year-old female (C.D.) was admitted to Forsyth Memorial Hospital in Winston-Salem, North Carolina, in January 1967, with a non-functioning kidney. History included multiple urinary tract infections. Nephrectomy was performed and the pathology report indicated chronic pyelonephritis and marked calyceal dilatation consistent with a calyceal diverticulum. The patient has been found to have microscopic hematuria. Serum creatinine was 1.4 mg percent. Eight years later, the patient has stable renal function but persistent hematuria including red blood cell casts.

Case 5 (#22). A 46-year-old female (R.C.) of Boone, North Carolina, complained to her family physician of dysuria, frequency, and intermittent discoloration of urine in July 1973. Urinalysis disclosed hematuria as well as bacteriuria and pyuria. Intravenous pyelogram and cystoscopy were normal. Infection was controlled by antibiotics, but her microscopic hematuria continues. Her creatinine was 0.9 mg percent.

Case 6 (#5). A 42-year-old male (L.W.) was evaluated for microscopic hematuria in January 1974, at the Quarryville Family Health Center after a family history of hereditary nephritis was obtained. Past history included chronic pyelonephritis, renal stones, urinary tract infections, and hematuria. Allergies were noted to penicillin and radiologic iodinated contrast media. Previous intravenous pyelogram showed shrunken, scarred kidneys. Cystoscopy and urine culture were negative. Microscopic hematuria and red cell casts were documented. Serum

creatinine was 1.2 mg percent. A high-frequency hearing loss was detected.

Results

Of 207 family members who were evaluated, 108 were affected with microscopic hematuria. In addition, five were presumed carriers because their parent and child were affected. Sixty-one percent were therefore involved. No cases of significant renal insufficiency in present or past family members could be found. The age range of the entire study group was 4 to 84 years. History of gross hematuria was obtained in only two patients. Red blood cell casts were found during a five-minute search in 32 percent of the total urines having microscopic hematuria. Most of the family did not have knowledge of their microscopic hematuria, even though many had urinalyses performed in the past. The hematuria was intermittent in some patients in whom several specimens were examined.

A history of urinary tract infections was elicited in 58 percent of the 180 from whom a history could be obtained. Males had a history of infection (31 percent) less often than females (82 percent). In retrospect, hematuria was often detected during hospitalization for other illnesses and usually not investigated. Five "carriers" (three females, two males) were free of hematuria on three different occasions, yet both a child and a parent were affected. Whether these five individuals are true carriers and never manifest their hematuria at any time is an unanswered question, since the hematuria was intermittent in some other affected members. Studies have suggested that several stresses may precipitate varying amounts of hematuria in affected individuals.^{5,6} These were not evaluated in this family.

Four of 11 members of one branch of the family were audiometrically

Table 1. Clinical data from Members of Family (Figure 1).

Patient	Sex	Age (Years)	Gross Hematuria	Microscopic Hematuria	RBC Casts	NHL*	Proteinuria (0 = 4+)	Serum Creatinine (n = 0.5 - 1.3 mg%)
1	F	77	0	+	+	+	0	1.9
2	F	51	0	+	+		0	1.4
3	F	25	0	+	0		0	1.0
4	F	55	0	0	0		0	
5	M	42	0	+	+	+	trace	1.2
6	M	15	0	+	0	0	0	0.8
7	M	11	0	0	0	0	0	
8	M	18	0	0	0	0	0	
9	F	17	0	+	+	0	0	0.8
10	F	12	0	0	0	0	0	
11	M	55	0	+	0		0	0.9
12	M	38	0	+	+	+	0	1.0
13	M	4	0	+	0		0	
14	M	50	0	+	0	+	trace	1.0
15	F	25	0	0	0		0	
16	F	38	+	+	+	0	0	1.0
17	F	40	0	+	0	0	0	1.2
18	F	22	0	+	0		0	1.0
19	F	49	0	+	0		0	
20	F	45	0	+	0		0	1.0
21	F	21	0	+	0		0	0.8
22	F	46	+	+	0		trace	0.9
23	F	17	0	+	+		trace	0.8
24	F	25	0	+	0		0	0.9
25	M	27	0	+	0		0	0.8
26	F	22	0	+	0		0	0.9

*NHL: Neural Hearing Loss

tested, as shown in Table 1, and found to exhibit high-frequency hearing losses. None of these was obvious clinically. Each of those involved also had another potential cause for the hearing loss, such as high noise environment, which therefore makes the significance of this finding unknown. There was no history of recurrent otitis media. No cataracts were found on routine examination in any of these patients. Slit lamp examinations were not carried out.

There seemed to be an increased history of allergy to penicillin and radiologic iodinated contrast media. Eighteen of 32 patients specifically questioned had a history consistent

with penicillin allergy. Five of the 12 who had an intravenous pyelogram gave a history compatible with an allergic reaction to the procedure. Most of those who had a reaction to the contrast media also were allergic to penicillin (four of five).

Table 1 shows data from a partial family pedigree which is representative of the entire group. The only exception is that all the cases with gross hematuria are in this pedigree. There also was a higher incidence of microscopic hematuria (81 percent compared with 61 percent). This may be related to a possible consanguineous marriage of patient #1. Her husband also has microscopic hematuria.

Table 2. Offspring of Affected Subjects and Normal Mates. Test for Expected 1:1 Distribution of Sexes in Autosomal Dominance.

Offspring	Father Affected			Mother Affected			Total Offspring		
	Affected	Normal	Chi Square	Affected	Normal	Chi Square	Affected	Normal	Chi Square
Male	17	13	0.53†	13	10	0.39†			
Female	17	11	1.29†	22	10	4.50*			
Total	34	24	1.72†	35	20	4.09*	69	44	5.53*

†Not significant at the 0.05 level (1 df)
*Significant at the 0.05 level (1 df) or $p < 0.05$

Discussion

Hematuria is a sign in many clinical situations. In the differential diagnosis of recurrent hematuria, nephritis can be distinguished from urologic conditions of the kidney or lower urinary tract by the presence of red blood cell casts. Once the casts are found, a renal biopsy is the most revealing diagnostic tool. This has greatly decreased the number of cases of "idiopathic" hematuria. Hereditary nephritis, of course, is proven by involvement of successive generations with progressive renal disease and nerve deafness in most of the affected males. Foam cells have been described in many of the renal biopsies.

The earliest reference to hereditary nephritis is that of Dickinson¹ in 1875. Many others have since described families with progressive renal disease and hematuria. The best known of these is Alport's¹⁰ study in 1927 which described the sensorineural hearing loss associated with hereditary nephritis.

Several articles since Baehr's¹ in 1926, have described non-progressive renal disease and hematuria. Non-progressive, intermittent and persistent hematuria have been discovered in all age groups. Detailed study of renal function and morphology generally does not show any evidence of signifi-

cant renal disease. In some cases a family history of hematuria or some type of nephritis was elicited; however, McConville,⁶ through careful family pedigree analysis, found successive generations of certain families with affected males and females suggesting the inheritable feature. In 1971, five kindreds with hereditary nephritis were reported by Chazan.⁷ One kindred of 34 people had a benign clinical course. Nerve deafness was reported.

The present family consisting of five generations has no renal associated mortality. Urinary tract infections are more common. Although nerve deafness is found in some of the family, possible explanations other than hereditary nephritis are present. None of the other associated abnormalities, such as musculoskeletal deformities, genitourinary tract abnormalities, or ocular problems are found in this study group.

Table 2 tests autosomal dominant inheritance in this family having benign hereditary nephritis. Table 3 shows the significance of sex ratios. Although the numbers are small, a general pattern emerges in this family of autosomal dominance with perhaps variable expressivity. There is a controversy as to the exact mode of inheritance of hereditary nephritis.¹²⁻¹⁵ The comparison of statistics in hereditary nephritis is fraught with a large

number of possible difficulties. The intermittency of the condition poses serious problems statistically^{12,16} unless those patients without hematuria are rechecked several times. Also, carriers may never have hematuria. Consanguineous marriage can be present, as is probable in this family, which may skew the genetic information.

A history of allergy is an interesting finding in this family. Other kindreds have been reported with an increased incidence of allergy in hereditary nephritis.^{13,17} Fanconi also pointed out this fact in patients with nephritis.¹⁸ The increased incidence in this small number of a kindred is only a clinical impression and may not represent a rate greater than that of the general population.

The renal involvement in benign hereditary nephritis is manifest, of course, by microscopic, and very rarely by gross, hematuria. Pyuria is common with or without symptoms of infection or positive cultures. A few of the patients in this study had elevated levels of serum creatinine. These members had previous urinary tract infections and one had a nephrectomy with histopathology consistent with pyelonephritis. The question remains exactly how and why the clinical pyuria, histologic pyelonephritis or glomerulonephritis, and its hereditary nature are related. Some have suggested that the urinary tract infections

oc
in
m
fe
ne
en
to
fa
(#
we
far

su
wi
ev
ha
Th
st
tu
far
bic
pro
Fu
sar

ph;
the
nej
has
seli

inance.

Chi Square

5.53*

Table 3. Significance of Sex Ratios.

Data	Ratio	Chi Square	Significance
Total men vs total women	53:60	0.43	NS
Affected vs normal subjects	69:44	5.53	p<0.05
Affected women vs normal women	39:21	5.40	p<0.05
Affected men vs normal men	30:23	0.93	NS
Normal men vs normal women	23:21	0.09	NS
Affected men vs affected women	30:39	1.17	NS

NS = Not Significant
p<0.05 = Statistically significant at $\alpha = 0.05$ level (1 df)

This study was supported by the Department of Family and Community Medicine with the Lancaster General Hospital, Lancaster, Pennsylvania.

References

1. Beehr G: Benign and curable form of hemorrhagic nephritis. JAMA 86:1001-1004, 1926
2. Wylie GF: Haematuria in children. Proc R Soc Med 48:1113-1117, 1955
3. Livaditis A, Ericsson NO: Essential hematuria in children: Prognostic aspects. Acta Paediatr Scand 51:630-634, 1962
4. Travis LB, Daeschner CW, Dodge WF, et al: "Idiopathic" hematuria. J Pediatr 60:24-32, 1962
5. Ayoub EM, Vernier RL: Benign recurrent hematuria. Am J Dis Child 109:217-223, 1965
6. McConville JM, West CD, McAdams AJ: Familial and nonfamilial benign hematuria. J Pediatr 69:207-214, 1966
7. Chazan JA, Zacks J, Cohen JJ, et al: Hereditary nephritis: Clinical spectrum and mode of inheritance in five new kindreds. Am J Med 50:764-771, 1971
8. Rogers PW, Kurtzman NA, Bunn SM Jr, et al: Familial benign essential hematuria. Arch Intern Med 131:257-262, 1973
9. Marks MI, Drummond KN: Benign familial hematuria. Pediatrics 44:590-593, 1969
10. Alport AC: Hereditary familial congenital haemorrhagic nephritis. Br Med J 1:504-506, 1927
11. Dickinson WH: On Renal and Urinary Affections. London, Longmans, Green and Co, 1878, p 379
12. Perkoff GT, Dolowitz DA, Stephen FE, et al: A follow-up of hereditary chronic nephritis. Arch Intern Med 102:733-746, 1958
13. Mulrow PJ, Aron AM, Gathman GE, et al: Hereditary nephritis: Report of a kindred. Am J Med 35:737-748, 1963
14. Shaw RF, Glover RA: Abnormal segregation in hereditary renal disease with deafness. Am J Human Genet 13:89-97, 1961
15. Cohen MM, Cassidy G, Hanna BL: A genetic study of hereditary renal dysfunction with associated nerve deafness. Am J Human Genet 13:379-389, 1961
16. Guthrie LG: "Idiopathic," or congenital, hereditary and family haematuria. Lancet 1:1243-1246, 1902
17. Whalen RE, Huang S, Peschel E, et al: Hereditary nephropathy, deafness and renal foam cells. Am J Med 31:171-186, 1961
18. Fanconi G, Kousiner C, Freschknect W: Die konstitutionelle bereitchaft nephrosesyndrome. Helv Paediatr Acta 6:199, 1951
19. Dubach UC, Minder FC, Antener I: Familial nephropathy and deafness. First observation of family and close relatives in Switzerland. Helvet Med Acta 33:36-43, 1966
20. Goldbloom RB, Fraser FC, Waugh D, et al: Hereditary renal disease associated with nerve deafness and ocular lesions. Pediatrics 20:241-252, 1957
21. Perkoff GT, Stephens FE, Dolowitz DA, et al: Clinical study of hereditary interstitial pyelonephritis. Arch Intern Med 88:191-200, 1951

lies. The ion poses 12,16 un-rematuria Also, car-ria. Con-resent, as hich may

interesting kindreds. ncreased reditary pointed nephri- in this s only a ot repre- of the

benign fest, of d very yuria is toms of . few of levated e mem- t infec- y with h pyc- emains clinical tis or editary e sug- citions

occur in hereditary nephritis superimposed on a glomerular lesion. In many cases the clinical and anatomical features have suggested glomerulonephritis;^{10,17,19} in others pyelonephritis appeared to be present.^{17,20,21} No study of renal histology has been documented in this family except that described in Case 4 (#2). We did not feel that renal biopsies were warranted in members of this family with such a benign history.

Hematuria of glomerular origin may suggest serious consequences. Patients with benign hereditary nephritis, however, appear to be quite different and have no progressive renal dysfunction. This has also been noted in previous studies.^{6,8,9} The presence of hematuria in the oldest member of this family, age 84, with no apparent morbidity, would presage a very good prognosis for the rest of the family. Further follow-up is, of course, necessary.

A large amount of patient and physician resources can be spared if the diagnosis of benign hereditary nephritis can be made in a family. This has obvious reference to genetic counseling as well as to the diagnostic

evaluation required. It has been reported that hereditary nephritis may be much more common than previously thought.⁷ It is interesting to note that in more than five generations of this large kindred, no one had been correctly diagnosed as having a hereditary renal disease. Undoubtedly, this was due to its benignity. Perhaps now there will be many more families with the benign form uncovered. This present kindred alone has moved into at least 14 states.

Acknowledgements

The authors wish to express their gratitude to Dr. Roger Ladda, Assistant Professor of Pediatrics and Chief of the Division of Genetics at Milton S. Eshshoy Medical Center who has made notable suggestions. Dr. John Krall, Associate Professor of Biostatistics, has been of great help with his mathematical acumen. The assistance of Dr. Havelock Thompson, Associate Professor of Pediatrics and Chief of the Division of Genetics, with genetic information, has been gratefully appreciated. The latter are of West Virginia University Medical Center. Our thanks is extended to the entire family who were so helpful during the tedious family study, especially Bertha, Lowell, and Alice.